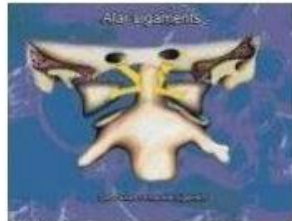
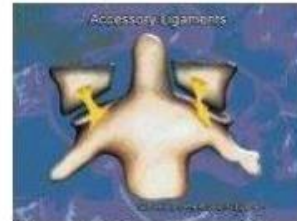


7. Motion in the A-P open mouth lateral bending projection: There is a significant abnormal lateral translation of C1 on C2 with an overhang bilaterally. Significant change is noted at the para-odontoid space bilaterally.

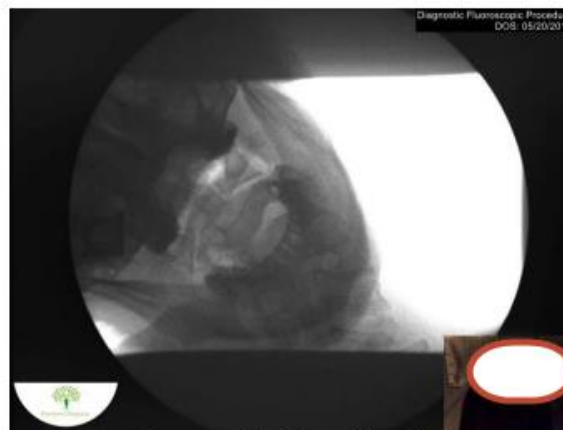This view examines the integrity of the alar and accessory ligaments either by the lateral overhang of C1 on C2 or by the changes in the para-odontoid spaces.



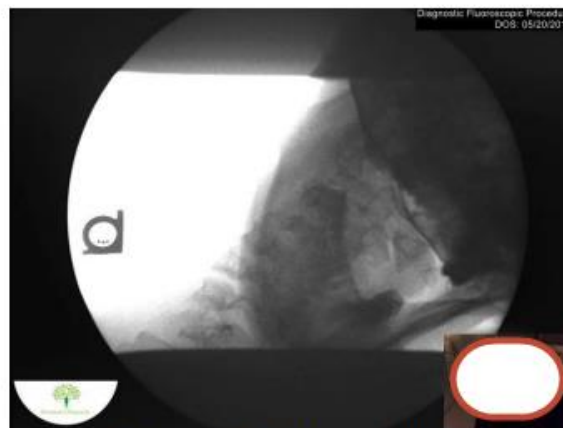C1 lateral mass overhang



Change in Para-odontoid space



Open mouth left lateral bending



Open mouth right lateral bending