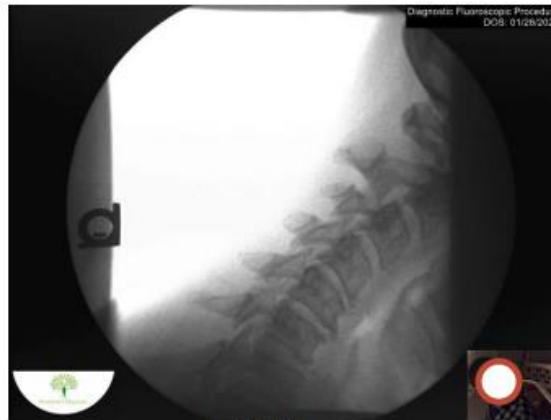


5. Motion in the oblique flexion projection: There is gapping of the facet joints at C6-C7 on the right and C7-T1 on the left.

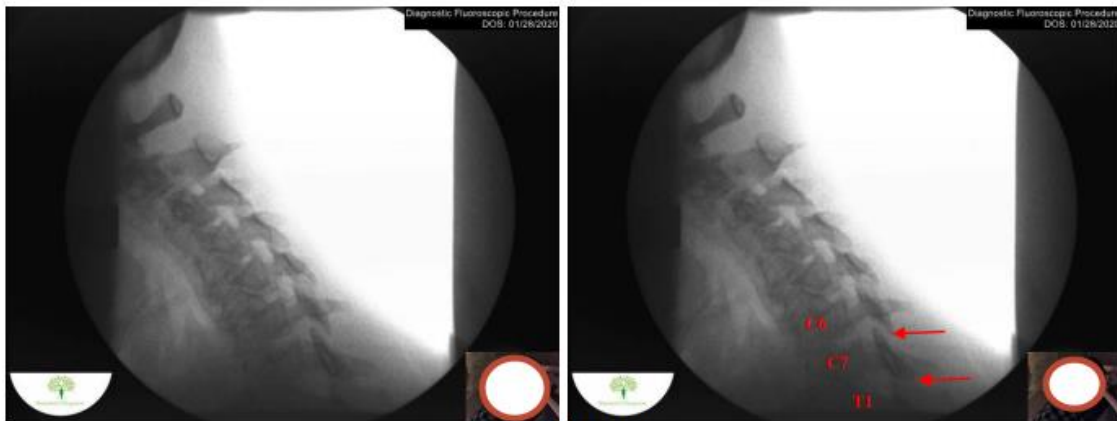
This view examines the integrity of the capsular ligaments by observing gapping of the facet joints, located on the posterior cervical spine (C2-C7), there are five capsular ligaments on the right and the left.



Capsular ligament damage



Left IVF flexion



Right IVF flexion