
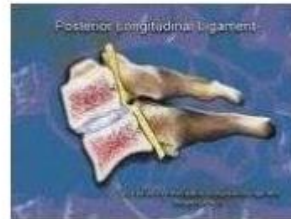


3. Motion in the neutral lateral projection to full flexion: There is a significant tilting of C1 laterally. There is an anterolisthesis of C3 on C4, C4 on C5 and C5 on C6. There is increased separation between the spinous processes at C3-C4, C4-C5, C5-C6, and C6-C7.

This view examines the integrity of the posterior longitudinal ligament demonstrated by a forward (anterior) movement of one vertebrae over the vertebrae below or by the posterior widening of the intervertebral disc space (increased disc angle).




Widening of posterior disc space

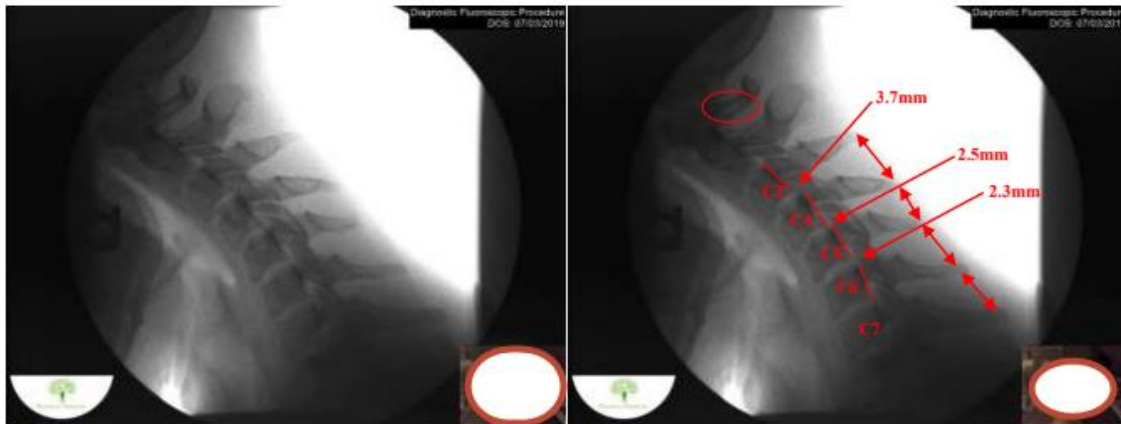

Anterolisthesis

The integrity of the interspinous ligament is evaluated in the lateral flexion view. Damage to this ligament results in increased separation of the spinous processes in flexion.



Damaged Interspinous Ligament



Full flexion projection